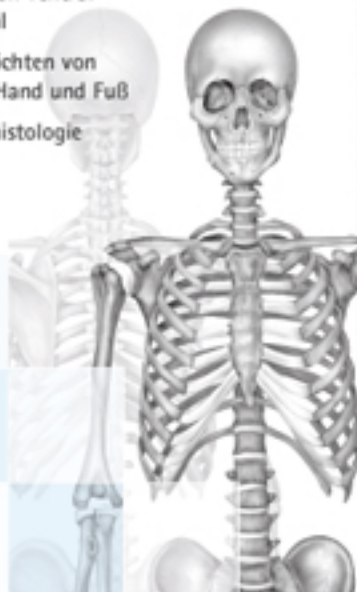


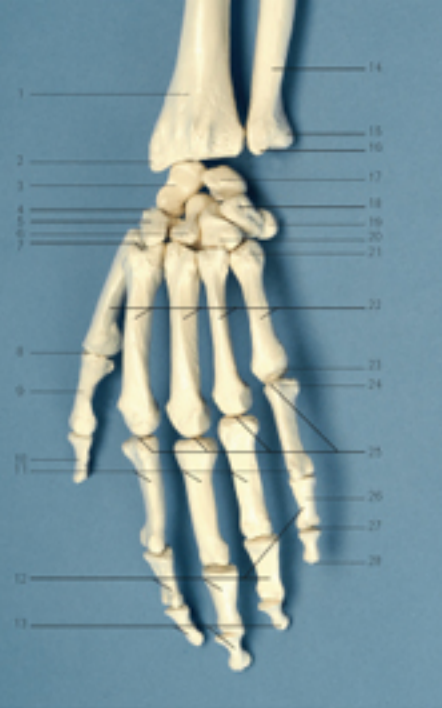# Das menschliche Skelett

- Ansicht von ventral und dorsal
- Detailansichten von Schädel, Hand und Fuß
- Knochenhistologie



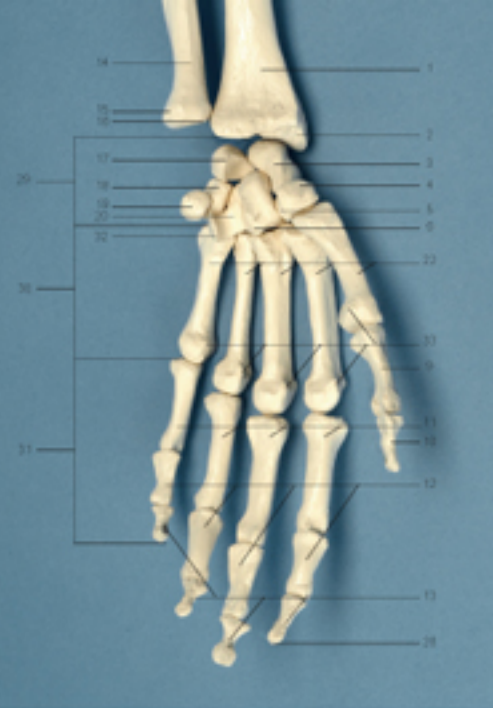**dieFachwelt**  
Verlag und Handelsgesellschaft mbH

www.dieFachwelt.de



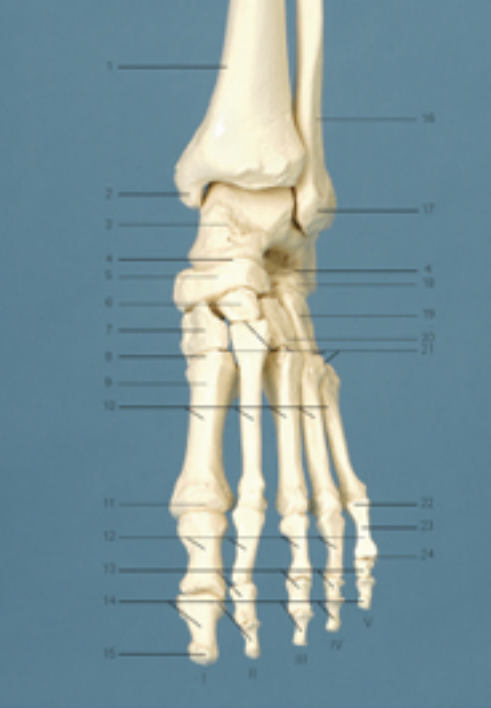Hand von dorsal (ii)

- |   |                               |
|---|-------------------------------|
| 1 Radius                                  | 10 Phalanx distalis I         |
| 2 Processus styloideus radii              | 11 Phalanges proximales II-V  |
| 3 Os scaphoideum                          | 12 Phalanges mediales II-V    |
| 4 Os trapezium                            | 13 Phalanges distales II-V    |
| 5 Os trapezoidum                          | 14 Ulna                       |
| 6 Os capitatum                            | 15 Processus styloideus ulnae |
| 7 Articulatio carpometacarpalis pollicis  | 16 Caput ulnae                |
| 8 Articulatio metacarpophalangea pollicis | 17 Os lunatum                 |
| 9 Phalanx proximalis I                    | 18 Os triquetrum              |



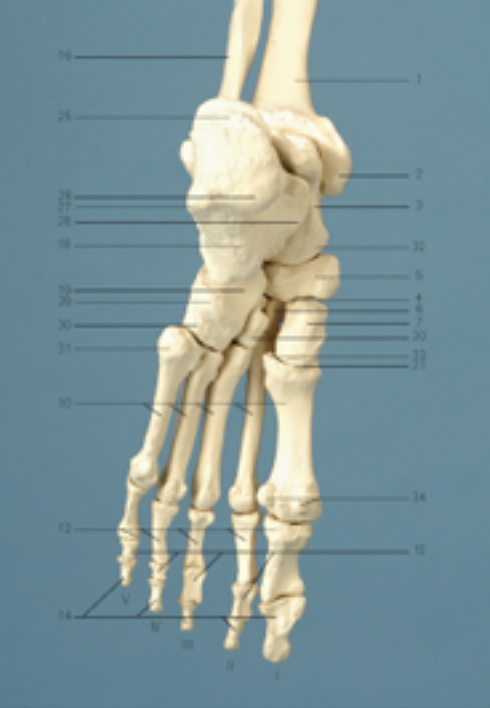Hand von palmar (ii)

- |  |  |
|--|--|
| 19 Os pisiforme                        | 29 Ossa carpi                          |
| 20 Os hamatum                          | 30 Ossa metacarpi I-V                  |
| 21 Basis ossis metacarpi V             | 31 Ossa digitorum I-V                  |
| 22 Ossa metacarpi I-V                  | 32 Hamulus ossis hamati                |
| 23 Caput ossis metacarpi V             | 33 Ossa sesamoides                     |
| 24 Basis phalangis V                   | 21-23 = Ossa metacarpi (5g. Metacarpi) |
| 25 Articulatio metacarpophalangea II-V |  |
| 26 Corpus phalangis V                  |  |
| 27 Caput phalangis V                   |  |
| 28 Tuberositas phalangis distalis      |  |



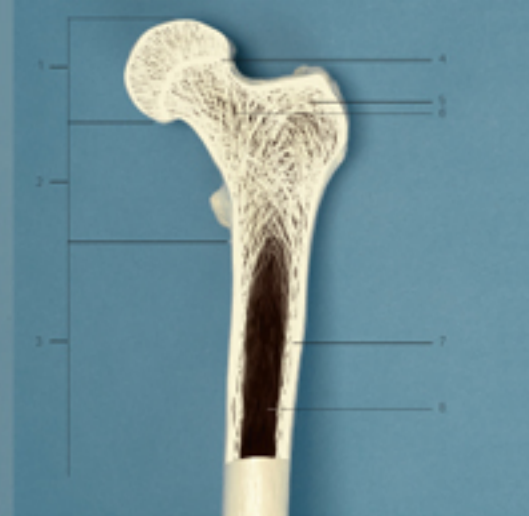
Fuß von ventral (ii)

- |   |   |
|---|---|
| I Hallux (Digitus primus)                       | 6 Os cuneiforme intermedium                     |
| II Digitus secundus                             | 7 Os cuneiforme mediale                         |
| III Digitus tertius                             | 8 Basis ossis metatarsi I                       |
| IV Digitus quartus                              | 9 Corpus ossis metatarsi I                      |
| V Digitus minimus (quintus)                     | 10 Ossa metatarsi I-IV (Lisfranc-Geleisenlinie) |
| 1 Tibia   | 11 Caput ossis metatarsi I                      |
| 2 Malleolus medialis                            | 12 Phalanges proximales I-V                     |
| 3 Talus   | 13 Phalanges mediales II-V                      |
| 4 Articulatio tarsi transversa (Chopart-Gelenk) | 14 Phalanges distales I-V                       |
| 5 Os naviculare                                 | 15 Tuberositas phalangis distalis I             |
|   | 16 Fibula                                       |



Fuß von plantar (ii)

- |  |   |
|--|---|
| 17 Malleolus lateralis                                       | 27 Processus lateralis tuberositatis calcanei |
| 18 Calcaneus   | 28 Sustentaculum tali                         |
| 19 Os cuboideum  | 29 Tuberositas ossis cuboidei                 |
| 20 Os cuneiforme laterale                                    | 30 Sulcus tendinis m. peronei fibularis longi |
| 21 Articulationes tarsometatarsales (Lisfranc-Geleisenlinie) | 31 Tuberositas ossis metatarsi V              |
| 22 Basis phalangis V   | 32 Caput tali                                 |
| 23 Corpus phalangis V  | 33 Tuberositas ossis metatarsi V              |
| 24 Caput phalangis V   | 34 Ossa sesamoides                            |
| 25 Tuber calcanei  | 8-10, 21, 33 = Ossa metatarsi                 |
| 26 Processus medialis tuberositatis calcanei                 |   |



Fuß von plantar (ii)

- |                            |                                  |
|----------------------------|----------------------------------|
| 1 Epiphyse                 | 5 Apophyse                       |
| 2 Metaphyse                | 6 Substantia spongiosa           |
| 3 Diaphyse                 | 7 Substantia compacta            |
| 4 knöcherner Epiphysenteil | 8 Markhöhle (hier ohne Fettmark) |

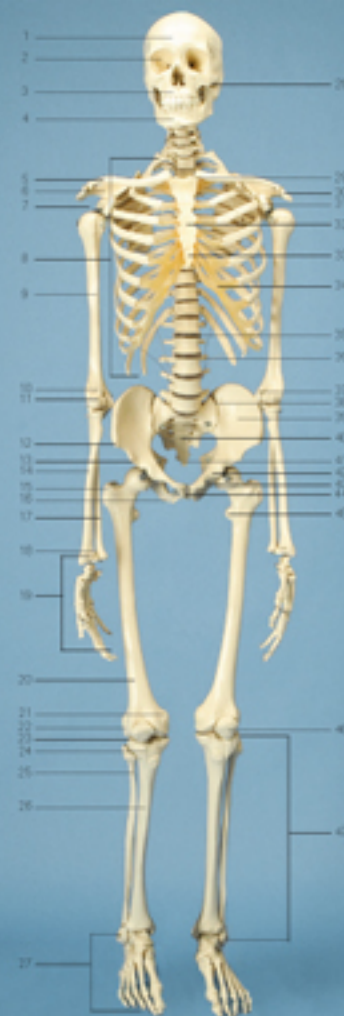Ebenfalls erhältlich:  
**Terminologie für Physiotherapeuten**



2015 © Die Fachwelt  
Verlags- und Handelsgesellschaft mbH  
Bestell-Nr.: 30310

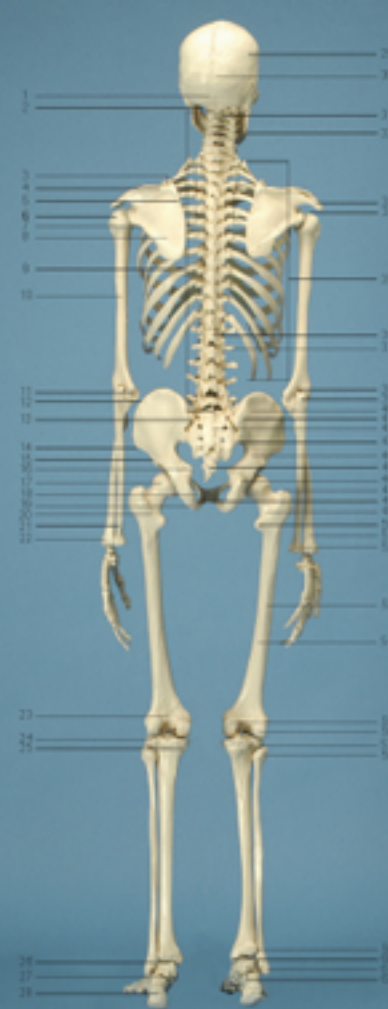www.dieFachwelt.de





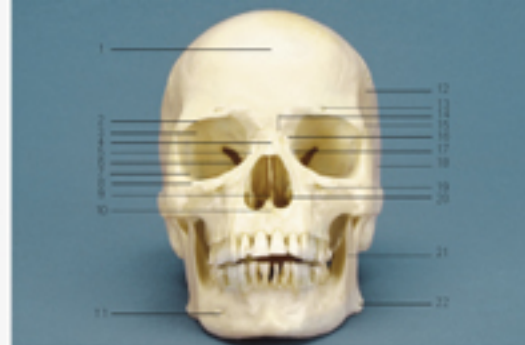### Skelett von ventral

- |                                    |                             |
|------------------------------------|-----------------------------|
| 1 Cranium                          | 44 Symphysis pubica         |
| 2 Orbita                           | 45 Trochanter minor femoris |
| 3 Maxilla                          | 46 Patella                  |
| 4 Mandibula                        | 47 Crus                     |
| 5 Clavicula                        |                             |
| 6 Scapula                          |                             |
| 7 Caput humeri                     |                             |
| 8 Costae 1-12                      |                             |
| 9 Humerus                          |                             |
| 10 Epicondylus medialis humeri     |                             |
| 11 Articulatio cubiti              |                             |
| 12 Spina iliaca anterior superior  |                             |
| 13 Spina iliaca anterior inferior  |                             |
| 14 Radius                          |                             |
| 15 Trochanter major femoris        |                             |
| 16 Tuber ischiadicum               |                             |
| 17 Ulna                            |                             |
| 18 Articulatio radiocarpae         |                             |
| 19 Manus                           |                             |
| 20 Femur                           |                             |
| 21 Epicondylus medialis femoris    |                             |
| 22 Epicondylus lateralis femoris   |                             |
| 23 Articulatio genus               |                             |
| 24 Tuber ositis tibiae             |                             |
| 25 Fibula                          |                             |
| 26 Tibia                           |                             |
| 27 Pes                             |                             |
| 28 Articulatio temporomandibularis |                             |
| 29 Articulatio sternoclavicularis  |                             |
| 30 Acromion                        |                             |
| 31 Processus coracoideus           |                             |
| 32 Corpus sterni                   |                             |
| 33 Processus xiphoides             |                             |
| 34 Cartilago costalis              |                             |
| 35 Discus intervertebralis         |                             |
| 36 Processus transversus           |                             |
| 37 Epicondylus lateralis humeri    |                             |
| 38 Articulatio ilioacralis         |                             |
| 39 Os ilium                        |                             |
| 40 Os sacrum                       |                             |
| 41 Os coccygis                     |                             |
| 42 Os pubis                        |                             |
| 43 Os ischii                       |                             |



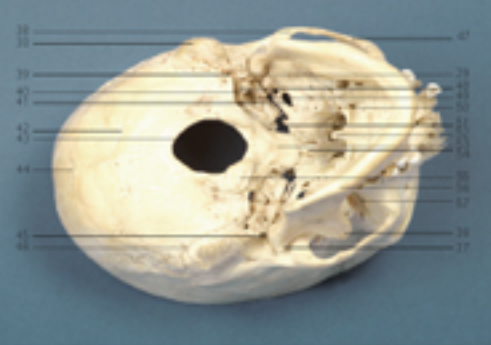
### Skelett von dorsal

- |  |                                    |
|--|------------------------------------|
| 1 Protuberantia occipitalis externa    | 42 Os sacrum                       |
| 2 Foramen mandibulae                   | 43 Spina iliaca posterior inferior |
| 3 Angulus superior scapulae            | 44 Os ilium                        |
| 4 Spina scapulae                       | 45 Os coccygis                     |
| 5 Margo medialis scapulae              | 46 Tuberculum pubicum              |
| 6 Caput humeri                         | 47 Trochanter major                |
| 7 Margo lateralis scapulae             | 48 Symphysis pubica                |
| 8 Scapula                              | 49 Collum femoris                  |
| 9 Columna vertebralis                  | 50 Trochanter minor                |
| 10 Humerus                             | 51 Radius                          |
| 11 Epicondylus medialis humeri         | 52 Processus styloideus ulnae      |
| 12 Crista iliaca                       | 53 Linea aspera                    |
| 13 Spina iliaca posterior superior     | 54 Femur                           |
| 14 Spina iliaca anterior superior      | 55 Condylus medialis femoris       |
| 15 Spina iliaca anterior inferior      | 56 Condylus lateralis femoris      |
| 16 Spina ischiadica                    | 57 Articulatio tibiofibularis      |
| 17 Caput femoris                       | 58 Caput fibulae                   |
| 18 Foramen obturatorum                 | 59 Syndesmosis tibiofibularis      |
| 19 Tuber ischiadicum                   | 60 Malleolus medialis              |
| 20 Crista intertrochanterica           | 61 Malleolus lateralis             |
| 21 Ulna                                | 62 Talus                           |
| 22 Processus styloideus radii          |                                    |
| 23 Facies poplitea                     |                                    |
| 24 Condylus lateralis tibiae           |                                    |
| 25 Condylus medialis tibiae            |                                    |
| 26 Articulatio talocruralis            |                                    |
| 27 Articulatio talocalcaneonavicularis |                                    |
| 28 Calcaneus                           |                                    |
| 29 Os parietale                        |                                    |
| 30 Os occipitale                       |                                    |
| 31 Axis                                |                                    |
| 32 Mandibula                           |                                    |
| 33 Acromion                            |                                    |
| 34 Articulatio humeri                  |                                    |
| 35 Costae I-XII                        |                                    |
| 36 Processus spinosus                  |                                    |
| 37 Processus transversus               |                                    |
| 38 Fossa olecrani                      |                                    |
| 39 Olecranon                           |                                    |
| 40 Linea glutea anterior               |                                    |
| 41 Linea glutea posterior              |                                    |



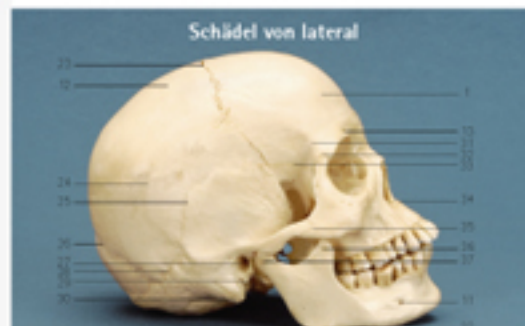### Schädel von frontal

- |                                  |                                       |
|----------------------------------|---------------------------------------|
| 1 Os frontale                    | 13 Foramen supraorbitale              |
| 2 Margo supraorbitale            | 14 Sutura intermaxillaris             |
| 3 Os frontale, Pars orbitalis    | 15 Os frontale, Processus zygomaticus |
| 4 Os nasale                      | 16 Sutura frontomaxillaris            |
| 5 Maxilla, Processus frontalis   | 17 Os lacrimale                       |
| 6 Fissura orbitalis superior     | 18 Os temporale                       |
| 7 Os zygomaticum                 | 19 Foramen infraorbitale              |
| 8 Margo infraorbitale            | 20 Concha nasalis inferior            |
| 9 Septum nasi osseum             | 21 Ramus mandibulae                   |
| 10 Maxilla, Processus alveolaris | 22 Angulus mandibulae                 |
| 11 Foramen mentale               | 23 Sutura coronalis                   |
| 12 Os parietale                  | 24 Linea temporalis superior          |



### Schädel von caudal

- |  |                               |
|--|-------------------------------|
| 25 Linea temporalis inferior           | 52 Spina nasalis posterior    |
| 26 Sutura lambdoidea                   | 53 Tuberculum pharyngeum      |
| 27 Peris acusticus externus            | 54 Vomer                      |
| 28 Sutura parietomaxillaris            | 55 Condylus occipitalis       |
| 29 Processus styloideus                | 56 Mandibula                  |
| 30 Processus mastoideus                | 57 Fissura orbitalis inferior |
| 31 Linea temporalis                    |                               |
| 32 Sutura frontozygomatica             |                               |
| 33 Sutura sphenofrontalis              |                               |
| 34 Spina nasalis anterior              |                               |
| 35 Sutura temporozygomatica            |                               |
| 36 Mandibula, Processus condylaris     |                               |
| 37 Mandibula, Processus condylaris     |                               |
| 38 Os temporale, Processus zygomaticus |                               |
| 39 Foramen stylomastoideum             |                               |
| 40 Foramen spinosum                    |                               |
| 41 Foramen ovale                       |                               |
| 42 Linea nuchalis inferior             |                               |
| 43 Foramen magnum                      |                               |
| 44 Protuberantia occipitalis externa   |                               |
| 45 Menus acusticus externus            |                               |
| 46 Sutura occipitomastoidea            |                               |
| 47 Arcus zygomaticus                   |                               |
| 48 Foramen jugulare                    |                               |
| 49 Canalis caroticus                   |                               |
| 50 Foramen palatinum majus             |                               |
| 51 Foramen lacerum                     |                               |



### Schädel von lateral